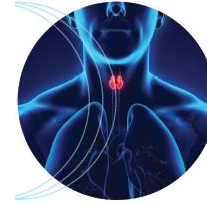


TRATTAMENTI PERCUTANEI
NELLA PATOLOGIA TIROIDEA:
stato dell'arte e prospettive future



Conclusions for Clinical Practice

Enrico Papini

Department of Endocrinology & Metabolism

Regina Apostolorum Hospital

Background

- The majority of thyroid nodules are benign at cytologic assessment
- Most of them do not require treatment
- A non-negligible minority become symptomatic or cause cosmetic concern
- Traditionally, surgery is the final treatment for many of these patients
- Thyroidectomy is a safe procedure but still carries risk of complications and loss of thyroid function.

Role of MITs for Benign Thyroid Nodules

- Non-surgical management avoids loss of thyroid function, negative impact on the QoL and use of expensive surgical facilities.
- Minimally-invasive procedures (MITs), characterized by different modalities of action and indications, are now accessible and thoroughly evaluated
- The appropriate use of MITs changes the natural history of thyroid lesions that become symptomatic or are enlarging over time.

Indications for Benign Thyroid Nodules

- Minimally invasive procedures are especially indicated for symptomatic non-functioning nodules
- Treatment may be also timely used to prevent further enlargement and symptoms occurrence in steadily growing lesions
- MITs should be used in nodular goiters only when a well-defined dominant lesion results in pressure symptoms
- Malignancy should be ruled out with two cytologic assessments
- US follow-up is appropriate after treatment.

Indications for Benign Thyroid Nodules (2)

- Thermal ablation may be offered as an alternative therapeutic strategy in selected hyperfunctioning nodules
- Thermal ablation is especially indicated in young patients with small lesions or when radioisotope treatment is not accessible and surgery is contraindicated or refused
- In large-size toxic nodules, a pre-treatment before ^{131}I may be used if an earlier control of hyperthyroidism and a more rapid nodule volume reduction are needed
- MITs are contraindicated in multinodular or autoimmune toxic goiters.

Percutaneous ethanol injection

- Percutaneous ethanol injection (PEI) is the first-line treatment for recurrent benign cystic lesions
- PEI may be used for the treatment of the fluid component of complex thyroid lesions before thermal ablation of the solid part of the nodule
- PEI is a rapid, inexpensive and safe outpatient procedure
- PEI should be performed in all centers with expertise in US-guided FNA as part of routine practice.

Thermal Ablation

- Laser and radiofrequency ablation provide significant volume decrease and improvement of pressure symptoms in symptomatic nodules
- Both techniques do not require anesthesia, are well tolerated, carry a low risk of complications and do not result in thyroid function abnormalities
- The whole procedure requires about 30 minutes and a short post-treatment observation is appropriate
- The preferential setting for thermal ablation procedures is day hospital
- These procedures require specific training and should be performed in high-volume thyroid centers.

Cost-benefit Ratio of Thermal Ablation

Advantages

- Reduction of nodule volume and symptoms
- No cosmetic damage
- Tolerable local pain
- No late hypothyroidism
- No heavy technology
- No general anesthesia
- Outpatient clinics (about 30 minutes)

Limits

- Persistence of the lesion: US & cytologic follow-up
- Well-trained operator
- Complications rare but potentially severe
- Probably not cost-effective in large goiter
- Regrowth after 3 years in a minority of cases.

HIFU and MW

- High-intensity focused ultrasound (HIFU) is a non-invasive treatment based on the generation of high-intensity ultrasound waves
- The time expenditure and the cost of the equipment are presently elevated
- Due to its target limitations, HIFU is a promising but not yet fully evaluated and cost-effective treatment.
- The ablation with microwaves (MW) should be considered as an experimental procedure due to the large bore of the devices and the still not assessed outcome.

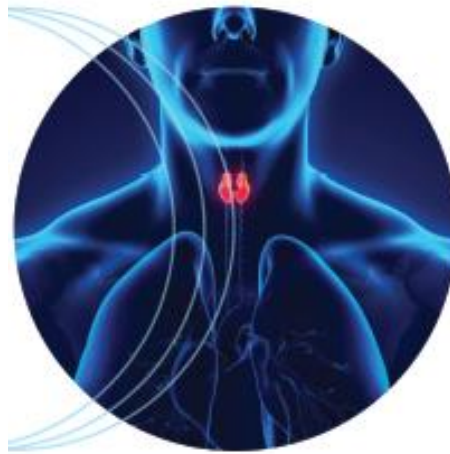Neck Recurrences of PTC

- Thermal ablation may be considered for local control of non radioiodine-avid neck recurrences of PTC in patients who are not candidate or refuse surgery
- Thermal ablation seems specifically indicated for small-size indolent recurrences in patients with previous neck dissection or surgical complications
- PEI should not be used due to its unpredictable diffusion and the consequences of ethanol leakage within neck tissues.
- MITs may be considered for large surgically unresectable disease persistences for an initial tumor debulking as part of a multimodality (EBRT, TKI) therapeutic approach.

Papillary Thyroid Microcarcinoma

- MITs may be considered as an alternative to the simple observation in patients with PTMC
- MITs was effective for the ablation of PTMC without evidence of multifocality or extrathyroid spreading in patients at high surgical risk
- This application should be reserved to selected cases with comorbidities or who refuse surgery and no evidence of aggressive behaviour.
- As a general rule, MITs treatment for malignancies must be performed after multi-disciplinary consultation and full information and consent of the patient.

Many thanks



and our work is still in progress!